



## CATS WITH CANCER

### Where to start

Laura Blackwood



**Practical relevance:** Many cats develop cancer and may or may not present with an obvious mass lesion. As our feline patients are living longer and their owners are increasingly seeking veterinary care, the apparent incidence and prevalence of cancer is increasing.

**Clinical challenges:** Neoplasia is a differential for many clinical presentations in cats. Often tumours are relatively advanced at the point of presentation, and this can make management difficult. In addition, many cats find clinic visits stressful and this can influence owners' decisions about treatment.

**Audience:** This review provides an overview of the approach to the feline cancer patient, and is aimed at all veterinary practitioners that see cats. It is intended as a starting point for more detailed discussions in accompanying articles in this special issue on feline oncology.

**Evidence base:** There is limited data on most feline tumours compared with tumours in canine or human patients, so a robust evidence base is often lacking.

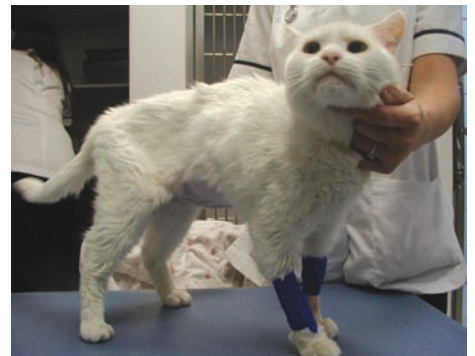### Cancer in cats

The most common tumours in cats are summarised with their presenting features and differentials in Table 1, and some are illustrated on page 368. Often, there may be non-neoplastic differentials for mass lesions as cats develop more granulomatous lesions than other species. They can also develop quite marked lymphadenopathy due to reactive or infectious causes. Furthermore, extranodal lymphoma can arise at any site, and is much more common in feline patients than in their canine counterparts, as are the alimentary/abdominal and cranial mediastinal forms of the disease.

### Clinical signs

Patients with cancer may present with a mass lesion (eg, a palpable mammary lesion) or with signs secondary to a mass such as halitosis, poor grooming or a malodorous coat in those with oral masses. The different behaviour patterns of individual cats affect how quickly mass lesions are noted and, unfortunately, many cats present late in the disease course. Cats with cancer may present with non-specific signs, such as alterations in appetite, reduced activity levels or weight loss (Figure 1). Nonetheless, a great deal of information can be obtained from clinical examination in cats, as abdominal masses are often readily palpable, and changes in thoracic compressibility may be apparent where there is a cranial mediastinal mass.

Some cats present with clinical signs of metastatic disease rather than signs relating to the primary tumour. This is seen most often in cases of



**Figure 1** Elderly male neutered (MN) domestic shorthair (DSH) cat, which presented with weight loss due to alimentary and renal lymphoma

**Laura Blackwood**

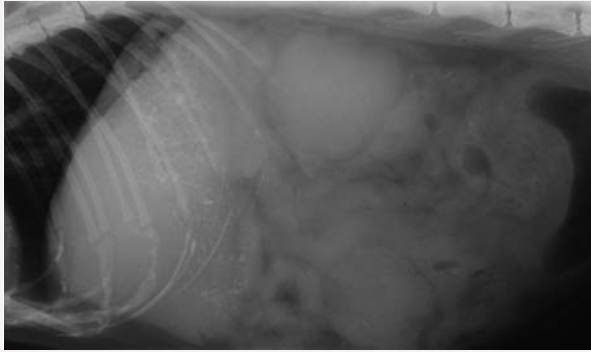
BVMS PhD MVM CertVR DipECVIM-CA (Onc) MRCVS  
RCVS & European Specialist in Veterinary Oncology  
Small Animal Teaching Hospital,  
University of Liverpool, Chester High Road,  
Neston, Wirral, CH64 7TE, UK  
Email: L.Blackwood@liverpool.ac.uk



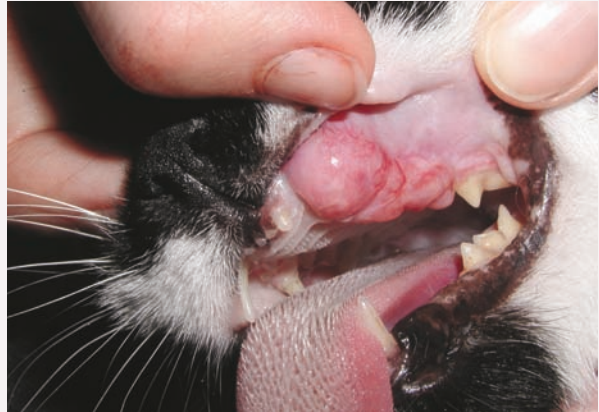**Table 1** Common tumours in cats – clinical signs and differentials

Tumour type	Site	Signalment/clinical signs/comments	Differentials
<b>LYMPHOMA</b>	<b>Alimentary</b>	Older cats Insidious weight loss Anorexia/reduced appetite Diarrhoea Occasionally vomiting Malabsorption/protein-losing enteropathy If gastric involvement, secondary gastritis/ulceration	All other causes of weight loss and gastrointestinal signs including: Inflammatory bowel disease Pancreatitis/triaditis Infectious/antibiotic-responsive disease Endocrine disease Renal disease All other causes of mesenteric lymphadenopathy including: Feline infectious peritonitis (FIP) Inflammatory bowel disease Metastatic neoplasia Pancreatitis Mycobacterial infection
	<b>Multicentric</b>	Any age Non-painful lymph node enlargement (may be regional) Anorexia Depression Non-specific malaise Pyrexia (Polyuria/polydipsia – uncommon)	Retroviral/viral, bacterial, fungal, mycobacterial (and protozoal) infections Immune-mediated disease Idiopathic lymphadenopathy Other haematopoietic malignancies Metastatic disease (regional)
	<b>Cranial mediastinal</b>	Younger cats, Orientals Respiratory distress Regurgitation/dysphagia Weight loss Lethargy, exercise intolerance Palpable reduction in cranial thoracic compressibility Cough (uncommon)	Thymoma Other cranial mediastinal lymphadenopathy Other causes of pleural effusion: Congestive heart failure Pyothorax FIP (Trauma/haemothorax)
	<b>Extranodal: nasal</b>	Nasal discharge Epistaxis Nasal obstruction Facial distortion Exophthalmos Reduced appetite	Other nasal tumours Chronic rhinitis/sinusitis
	<b>Extranodal: renal</b>	Malaise Anorexia Renomegaly (often bilateral) Azotaemia	Chronic renal failure Other renal tumours
	<b>Extranodal: central nervous system (CNS)</b>	Signs depend on site Rarely solitary – may find other sites on staging CNS lymphoma can be difficult to confirm: Extradural masses: no tumour cells in cerebrospinal fluid Bone marrow aspirate?	Other neoplastic CNS disease (especially meningioma) Inflammatory CNS disease Infectious CNS disease: Toxoplasmosis FIP Feline leukaemia virus (FeLV)/feline immunodeficiency virus (FIV) infection
<b>SQUAMOUS CELL CARCINOMA</b>	<b>Oral cavity</b>	Halitosis Unkempt coat Oral mass lesion (commonly sublingual)	Dental disease Fibrosarcoma Lymphoma Granuloma Other tumour (eg, osteosarcoma)
	<b>Rhinarium/pinna/eyelid/other cutaneous</b>	Plaque-like or papillated, scaly, crusty, crateriform or ulcerated mass Papillary or fungiform mass Often indurated (fixed and firm)	Eosinophilic granuloma Actinic keratitis (precursor of squamous cell carcinoma) Basal cell tumour
<b>MAMMARY CARCINOMA</b>	<b>Mammary glands</b>	Mass associated with mammary gland Size has prognostic significance (<2 cm better prognosis, >3 cm worse prognosis)	Sarcoma Benign mammary tumour Mammary hypertrophy/fibroadenomatous hyperplasia
<b>SOFT TISSUE SARCOMA</b>	<b>Injection site Other cutaneous/subcutaneous</b>	Firm, poorly circumscribed mass May be multilobular Alopecia/ulceration	Cutaneous: Basal cell tumour Mast cell tumour Squamous cell carcinoma Subcutaneous: Mast cell tumour Other sarcoma Abscess (Lipoma – relatively uncommon)

### Lymphoma

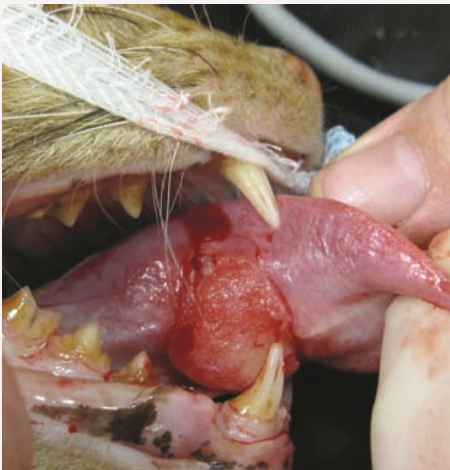

Intestinal lymphoma, with renal involvement, in the elderly MN DSH cat pictured in Figure 1. This lateral abdominal radiograph shows gastric/intestinal gravel sign consistent with partial obstruction, a large mid-ventral abdominal soft tissue mass, and a rounded irregular enlarged renal shadow. The cat responded well to cyclophosphamide, vincristine and prednisolone, but on relapse did not respond to rescue therapy. Survival time was 7 months

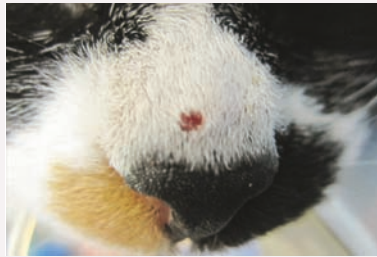

Oral mass, diagnosed as lymphoma, in an adult female neutered (FN) DSH cat (recently rescued). The cat responded well to cyclophosphamide, vincristine and prednisolone and had a survival time of more than 2 years

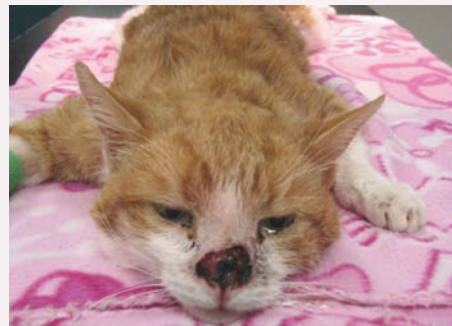### Squamous cell carcinoma



Unresectable sublingual and lingual squamous cell carcinoma in an 8-year-old MN DSH cat. There was no response to palliative medical therapy or chemotherapy and the cat was euthanased 3 weeks after diagnosis

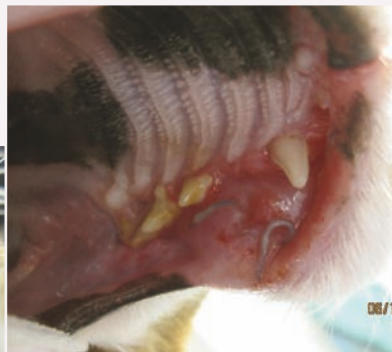
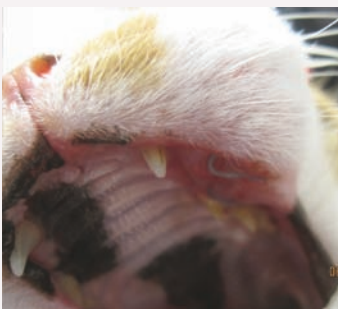
Early cutaneous squamous cell carcinoma in a 17-year-old FN DSH cat that presented for postoperative radiation therapy of a labial squamous cell carcinoma. Surgical excision of this mass was curative, but there was relapse at the site of the labial squamous cell carcinoma after 5 months

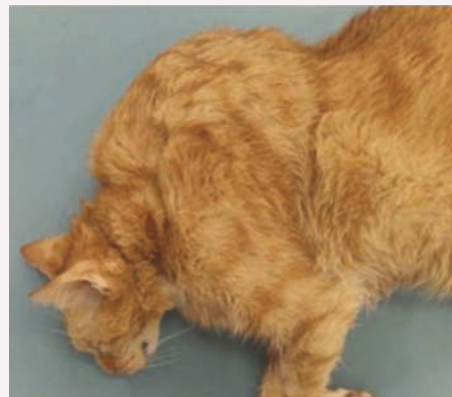

Advanced rhinarial squamous cell carcinoma in an 8-year-old MN DSH cat, presented for radiation therapy. Short-term palliation was achieved

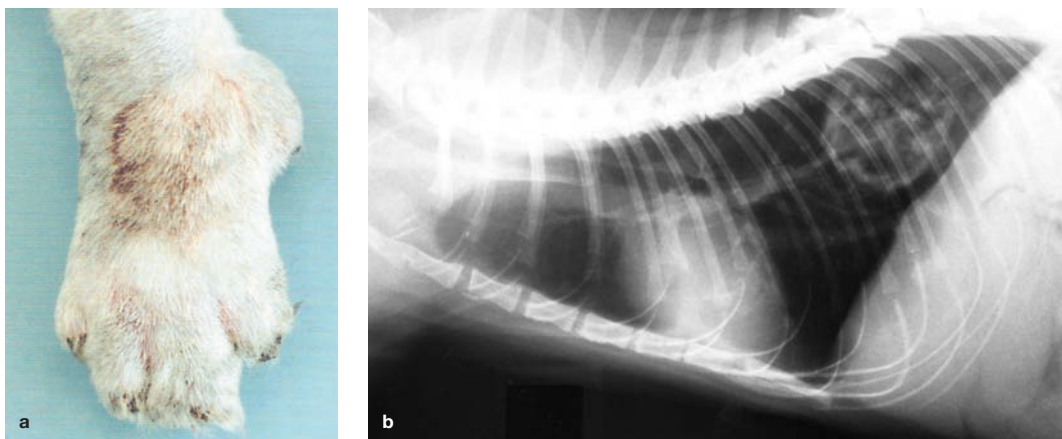
### Soft tissue sarcoma



Maxillary fibrosarcoma causing gross facial distortion in an 11-year-old FN DSH cat. Suture is present from a recent biopsy

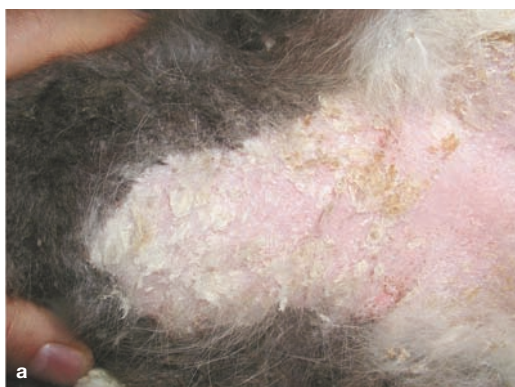

Large soft tissue sarcoma (suspected injection site-associated sarcoma) in an adult MN DSH cat

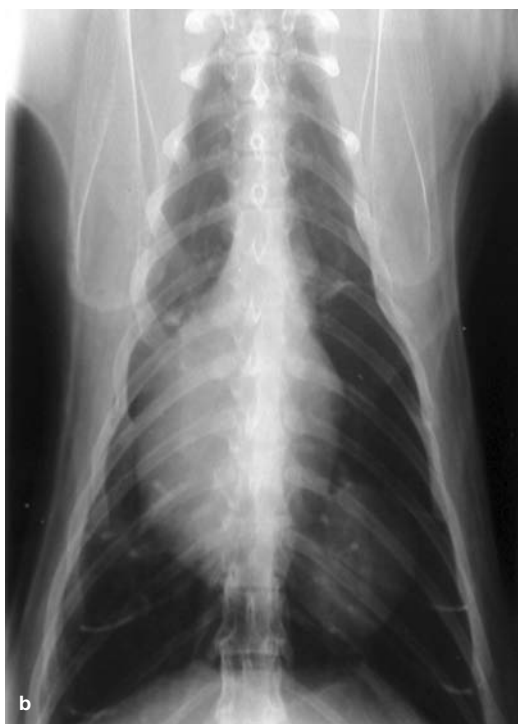

**Figure 2** Lung-digit syndrome in an adult DSH cat. The patient presented to the orthopaedic service at the author's hospital for investigation of lameness and digital swellings (a). A pulmonary mass was found on thoracic radiography, as demonstrated by the right lateral view shown in (b). Reproduced from Corr and Blackwood (2003)<sup>2</sup>

lung-digit syndrome (Figure 2), where patients present with metastatic lesions of the digits (usually multiple) secondary to primary lung tumours.<sup>1,2</sup> Cats may also infrequently present with signs due to paraneoplastic disease. Cutaneous manifestations of neoplasia are uncommon but dramatic (eg, paraneoplastic alopecia in pancreatic, hepatic or bile duct carcinoma; exfoliative dermatitis with thymoma), and neoplasia should be a differential for cats presenting with these dermatological complaints (Figure 3).<sup>3-6</sup>



**Figure 3** Severe exfoliative dermatitis, seborrhoea and alopecia in a 14-year-old MN DSH cat that was presented as a dermatology referral (a). A pulmonary mass was found on thoracic radiography (dorsoventral view, b) and confirmed cytologically as an adenocarcinoma. Courtesy of Dr Tim Nuttall



## Key to appropriately managing cancer cases is having an accurate diagnosis.



### Getting a diagnosis

Key to appropriately managing cancer cases is having an accurate diagnosis, so that correct tumour staging can be performed and the best treatment recommended. Clinical features typical of a malignant tumour include rapid growth, fixation, invasion into deep tissues or overlying skin, ulceration and poorly defined margins. Clinical criteria can suggest a lesion is malignant, but apparently less aggressive behaviour should not result in the lesion being assumed benign. For example, aggressive mesenchymal tumours may appear well demarcated due to pseudocapsule formation. Sampling of mass lesions by cytology or histology is required.

The advantages and disadvantages of cytology and histopathology are summarised in the box below. Neither technique is 100% sensitive or specific in the diagnosis of tumours, although histopathology remains the gold standard.

### Comparison of cytology and histopathology

#### Cytology

- ❖ Relatively non-invasive
- ❖ Minimal restraint often sufficient
- ❖ Minimal tissue disruption
- ❖ Rapidly performed
- ❖ Results obtained quickly
- ❖ Cheaper
- ❖ No architectural detail
- ❖ Small numbers of cells examined – representative?
- ❖ Limited assessment of tumour type/grade

#### Histopathology

- ❖ More invasive
- ❖ General anaesthesia (or sedation) required
- ❖ Moderate tissue disruption
- ❖ More time-consuming
- ❖ Delay in results
- ❖ More expensive
- ❖ Architecture apparent
- ❖ Larger sample size – more representative?
- ❖ More accurate assessment of tumour type/grade

### Sampling by cytology

Cytology will usually differentiate between neoplastic and inflammatory lesions, and determine if tumours are malignant or benign. Cytology will also broadly ascertain tumour type (epithelial, mesenchymal or round cell tumour) but not the exact histogenesis; for example, sarcoma may be diagnosed, but histology will be required to determine the tissue of origin. There are other pitfalls to be wary of too: dysplastic epithelial or mesenchymal cells may mimic neoplastic change, and this is particularly problematic where there is concurrent inflammation.

Fine needle aspirates may be non-diagnostic due to low yield in some sarcomas. In cats, fine needle aspirates from lymph nodes are less likely to be diagnostic of lymphoma than in dogs, and it may be impossible for the clinical pathologist to differentiate lymphoma from a very reactive node; in many cases, biopsy is required. However, fine needle aspirates are very useful in extranodal lymphoma, and cytology of bone marrow may help support a diagnosis of CNS lymphoma as many affected cats are reported to have bone marrow involvement.

Cytology is also very useful in making a diagnosis from fluid samples. In cases of suspected neoplastic effusion, the detection of tumour cells in samples with low cellularity can be enhanced by preparing a sediment smear (see box).

### Sampling by biopsy

Biopsy is more invasive than harvesting samples for cytology, and there are increased risks of haemorrhage, transplantation of tumour cells, compromise of future surgery and damage to adjacent structures, although good technique minimises these risks. If suspicious of an infectious cause, it is advisable not to fix all biopsy tissue so the procedure does not have to be repeated to perform bacterial, fungal or mycobacterial culture.

✦ **Tru-cut biopsies** are useful for sampling parenchymatous organs non-invasively, but samples are small. Tru-cut biopsies of lymph nodes are not recommended as they are often insufficient to allow diagnosis of lymphoma, and may be no more sensitive than fine needle aspiration for the detection of metastatic disease.

✦ **Punch biopsies** are most often used for skin lesions, but can be used for sampling oral masses (although the defect is harder to close than an inverted wedge). They are of little value for lymph node biopsy.



✦ **Grab biopsies** tend to be used to sample tissue from the respiratory and alimentary tracts. Biopsy of suspected nasal tumours is best achieved through the external nares with a small set of 'cup' biopsy forceps. If these are not available, a sharp bone curette can be used to try to scoop out tumour, or a cut-off urinary catheter can be inserted into the mass, with gentle rotation and suction

### Sediment smear technique

A sediment smear can be prepared in practice using the urine setting on a StatSpin (or similar benchtop) centrifuge; the aim is to use the slowest spin to minimise cell damage/destruction. The majority of the supernatant is decanted off and the sediment is gently resuspended before making the smear or line smear (as illustrated here), and these samples are submitted along with the fluid sample in EDTA. For very haemorrhagic samples, the laboratory can prepare a buffy coat smear to maximise the chances of finding tumour cells. Care is required in interpreting fluid samples from body cavities, as reactive mesothelial cells can look similar to neoplastic epithelial cells; submission to a clinical pathologist is recommended.

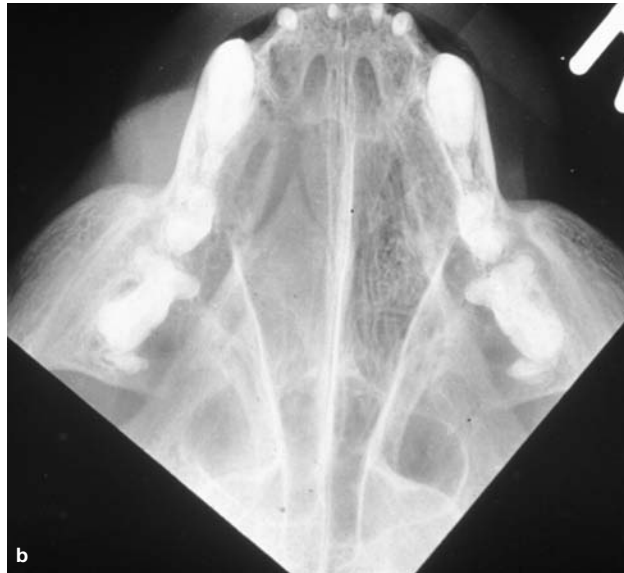
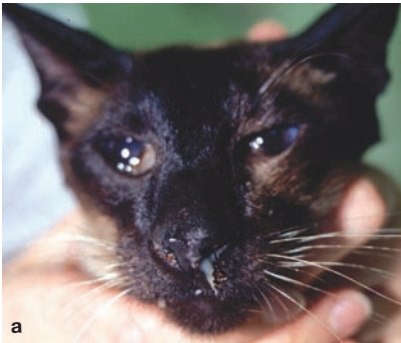
(a) 'Line smear' from a thoracic effusion. The smear is prepared in the same way as a blood smear, but instead of creating a feathered edge, the aim is to create a line where cells are concentrated together. This is achieved by abruptly stopping smearing mid-way and lifting the smearing slide off, creating a line. The technique is illustrated in (b) and (c) using a bloody sample for easy visualisation



The chances of detecting tumour cells in effusion samples with low cellularity can be increased by preparing a sediment smear.





**Figure 4** (a) Unilateral nasal discharge in a 2-year-old MN Siamese cat. Biopsies in this case confirmed lymphoma. When taking biopsies from nasal tumours, it is important first to measure the grab biopsy forceps or cut-off urinary catheter – either against the patient so that the biopsy/catheter is not inserted any further than the level of the medial canthus, or against a dorsoventral intraoral radiograph (b) to ensure the biopsy/catheter ends within tumour and cranial to the cribriform plate

applied to harvest a sample. Whichever method is employed, the biopsy forceps/catheter should first be measured against the patient and the distance from the external nares to the medial canthus marked on the biopsy tool (or the catheter cut just short of this length); it is vital that the instrument is introduced no further than this point, to avoid the risk of biopsying brain tissue (Figure 4).

❖ **Endoscopic grab biopsies** from the gastrointestinal tract produce small, superficial samples composed mainly of mucosa. Multiple biopsies should be taken. In addition, biopsies from both duodenum and ileum (ie, using both upper and lower endoscopy) are recommended in cases where the major differentials are inflammatory bowel disease or lymphoma, as biopsy from a single site is likely to fail to identify lymphoma in a significant proportion of

cases.<sup>7</sup> Full thickness biopsies may be required in feline intestinal disease.

❖ **Incisional biopsies** allow visualisation of tissue and harvesting of larger samples than Tru-cut, punch or grab biopsies. Wedge biopsies are recommended to sample accessible masses, such as oral masses. When harvesting incisional biopsies, ulcerated and necrotic areas should be avoided, as should the junction between normal and neoplastic tissue, which would otherwise increase the surgical field. The biopsy site should be planned so that the entire biopsy tract can be removed at definitive surgery.

❖ **Excisional biopsy** is indicated for lymph nodes, some intestinal masses and for most mammary tumours in cats, but is otherwise seldom indicated. This is because inappropriate excisional biopsy can jeopardise future treatment, and the first surgery offers the best chance of cure. This is especially true for cats with soft tissue sarcomas. Reported recurrence rates for feline sarcoma are in excess of 70%, and every effort should be made to avoid inappropriate management.

**Inappropriate excisional biopsy can jeopardise future treatment.**



#### Sampling of feline skin lesions

Benign epithelial tumours and papillomas are uncommon in cats, and 50–60% of skin tumours are malignant. Non-neoplastic conditions may also present as proliferative or ulcerative lesions, including eosinophilic granuloma complex, flea allergic dermatitis, mycoses, poxvirus, dermatophytoses and immune-mediated disease. The commonest skin tumours are basal cell tumours (probably these were over-diagnosed historically), squamous cell carcinomas, mast cell tumours and fibrosarcomas.<sup>8</sup> Excisional biopsy is generally not recommended for feline skin tumours. Fine needle aspiration or biopsy is recommended to identify those lesions where local excision is inappropriate.

#### Clinical staging

Clinical staging involves assessment of the primary tumour (T), including involvement of adjacent structures, and assessment for metastasis to local and regional lymph nodes (N) and distant sites (M). The aim of TMN staging is to inform clinical decision making and ensure the best treatment possible under the individual circumstances of the case.

Assessment of the primary tumour should include evaluation of extent, by clinical examination and appropriate diagnostic imaging

## Exploratory laparotomy and tumour staging

The importance of clinical staging is sometimes forgotten during abdominal surgery, particularly when exploratory surgery is performed and a mass is discovered. At the time of surgery, there is the opportunity to assess the primary tumour/mass and also to evaluate other organs. Some pointers for getting the best outcome from exploratory laparotomy are given below.

- ❖ Have a plan: do not perform a 'peek and shriek'!
- ❖ Achieve adequate access
- ❖ Biopsy (or fine needle aspirate) any suspicious lesions
- ❖ Examine/fine needle aspirate/biopsy local and regional nodes
- ❖ Examine/fine needle aspirate/biopsy parenchymatous organs
- ❖ If you resect a mass
  - Think about your margins
  - Resect adhesions with the mass
  - *Discard contaminated instruments* (tumour or gastrointestinal contents)
- ❖ Decide if you should place a feeding tube
- ❖ (Keep a fresh piece of tissue for culture if suspicious of a granulomatous lesion)

or endoscopic techniques, and a diagnosis of tumour type based on cytology or histology (see earlier). The sensitivity of tests should be borne in mind. For example, clinical examination of a maxillary squamous cell carcinoma may suggest a less extensive tumour than would radiography, which in turn is less sensitive than computed tomography (CT).

Exploratory laparotomy in a suspected or confirmed cancer patient should always contribute to tumour staging (see box).

### Lymph node evaluation

Carcinomas most commonly metastasise by the lymphatic route, and local and regional lymph nodes should be evaluated in cats with carcinoma by palpation (eg, of axillary and inguinal nodes in cats with mammary tumours), diagnostic imaging, and aspiration and cytology. Mast cell tumours also metastasise by the lymphatic route, but reported metastatic rates for cutaneous mast cell tumours in cats vary, ranging from 0–22%, and most histologically well-differentiated tumours have a low metastatic potential. Poorly differentiated tumours are more malignant. (Visceral mast cell tumours are generally malignant and metastases may be widespread at presentation.)

### Thoracic radiographs

Primary lung tumours are relatively readily diagnosed radiographically (Figures 2 and 3). Compared with dogs, cats less frequently develop classical well-defined 'cannon ball' metastases, and metastatic disease can appear as ill-defined mass lesions or diffuse alveolar, interstitial or mixed patterns (Figure 5).<sup>9</sup> A bronchial component is relatively common in metastatic patterns in bronchoalveolar carcinoma.<sup>10</sup> Cytology of lung aspirates or bronchoalveolar lavage fluid may be required to confirm a diagnosis.



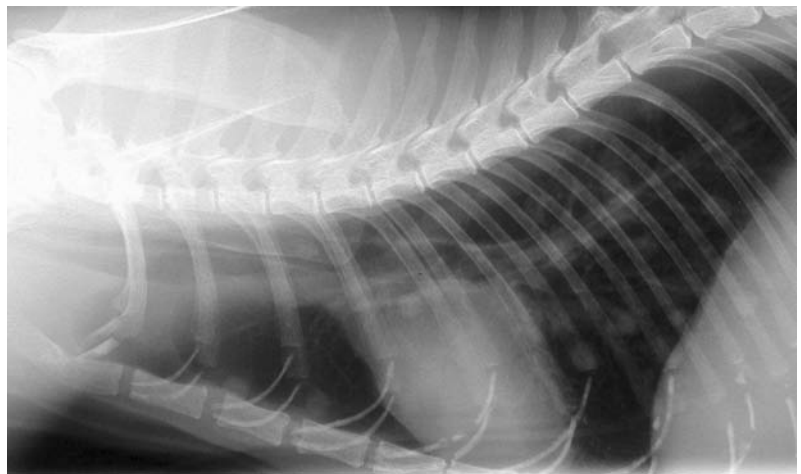
Compared with dogs, cats less frequently develop classical well-defined 'cannon ball' metastases.

### Abdominal ultrasound

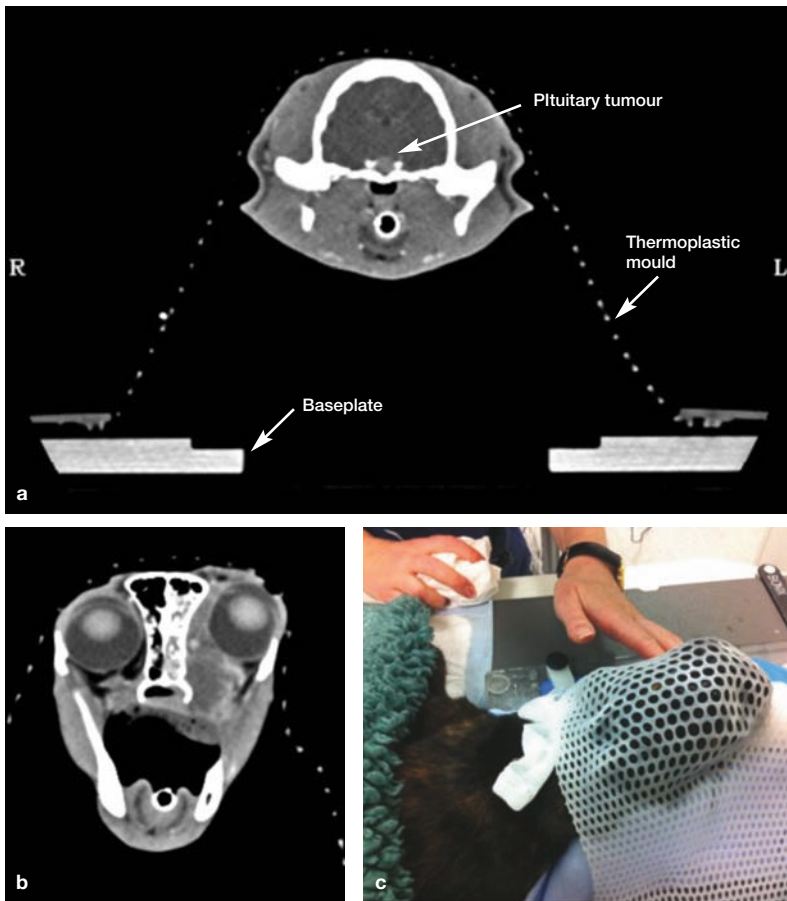
Mass lesions and markedly enlarged lymph nodes may be detectable on abdominal palpation, but abdominal ultrasound allows detection of lesions not apparent on clinical examination, including lesions within hepatic, splenic and renal parenchyma, as well as changes in layering of the gastrointestinal tract and more subtle lymph node enlargement.

### Advanced imaging

Advanced imaging is increasingly available for veterinary patients, and is very valuable. However, it is expensive, and, as with any diagnostic test, should be utilised with full consideration of the value of the study and the cost implications for future management of the case. When mass lesions are found, samples should be harvested to allow a diagnosis.



**Figure 5** Lateral thoracic radiograph (inflated) of an elderly FN DSH cat. Multiple poorly defined soft tissue opacities are seen, which represent metastases from an unknown primary. There are also increased interstitial and bronchial markings



**Figure 6** (a) Transverse CT scan of an 8-year-old MN DSH cat with poorly controlled diabetes mellitus due to acromegaly, showing a mass in the pituitary fossa. The positioning device seen is a thermoplastic mould, which is shaped round the patient, whose head is supported on a mouldable pillow (not visible on this window). The mould is secured to a baseplate. (b) CT scan of a 7-year-old FN cat with a nasal tumour (extending into the orbit) after positioning in the same mould system (c)

❖ **Computed tomography** is most useful for evaluation of tumours where there is likely to be skeletal involvement, and is generally required for radiation planning (Figure 6). CT is also useful for the identification and staging of pulmonary neoplasia (including evaluation of bronchial nodes) and pulmonary metastatic disease.

❖ **Magnetic resonance imaging** is useful for the evaluation of soft tissue lesions and lesions in the CNS. It is particularly valuable in planning surgery in cases of soft tissue sarcoma.

#### Blood tests

Most blood tests do not help to make a diagnosis of cancer in cats, but they can help to identify common co-morbidities, and this can be very important in decision making.

On haematology, there may be a mild non-regenerative anaemia and a stress haemogram. These are the commonest findings in lymphoma patients.<sup>11</sup> Abnormal circulating cells and/or lymphocytosis is relatively



uncommon. Even in cats with leukaemia, there may be no abnormal circulating cells on haematology.

On biochemistry, changes are often non-specific and may reflect stress (eg, hyperglycaemia), co-morbidity or organ involvement (eg, hypoalbuminaemia in diffuse alimentary lymphoma). Urine specific gravity should be measured in azotaemic patients to confirm renal or pre-renal origin. (Urine specific gravity will be low in azotaemic hypercalcaemic patients even if the renal concentrating ability is normal because of antagonism of antidiuretic hormone.) Paraneoplastic hypercalcaemia is uncommon in cases of feline lymphoma, and is more commonly seen in patients with myeloma. Hypercalcaemia can also be seen with other tumours, particularly carcinomas.

In the UK, most cats with lymphoma now are FeLV antigen negative on ELISA. However, testing is valid where there is an infection risk to others, and where concurrent disease may affect treatment decision making.

**The aim of staging is to inform clinical decision making and ensure the best treatment possible under the individual circumstances of the case.**





**Figure 7** An 8-year-old MN DSH cat, which presented with an early mandibular fibrosarcoma. A partial mandibulectomy was performed, and a feeding tube placed, visible in (a), which shows the patient 2 days postsurgery. (b) The cat 6 months later. In this case, surgery was curative, but complete excision of feline oral tumours is frequently impossible

**Surgery remains the mainstay of treatment for solid tumours**



### Treatment options and considerations

In broad terms, surgery and radiotherapy can be considered as local treatments for primary disease or primary disease with local lymph node involvement, and chemotherapy as systemic treatment for disseminated disease.

#### Surgery

In cats, treatment of primary mass lesions may be limited by small patient size and difficulties in achieving wide local excision. However, surgery remains the mainstay of treatment for solid tumours.

Mammary tumours are most often resected by radical mastectomy, as most feline mammary tumours are malignant. Both axillary and inguinal lymph nodes on the affected side should be resected en bloc with the mammary tissue, but often the axillary nodes are not removed if deemed normal as they are less readily identifiable than the inguinal nodes. Local excision of malignant mammary tumours is associated with a high rate of recurrence.

Oral tumours are often unresectable by the time of presentation: the overall cure rate for oral squamous cell carcinoma is less than 5%. Where excision is possible, consideration should be given to placing a feeding tube at the time of surgery to facilitate postoperative care and recovery, as cats may cope less well with, for example, mandibulectomy than dogs do, particularly in the immediate postoperative period. Cosmetic and functional results may be very good in the longer term (Figure 7).

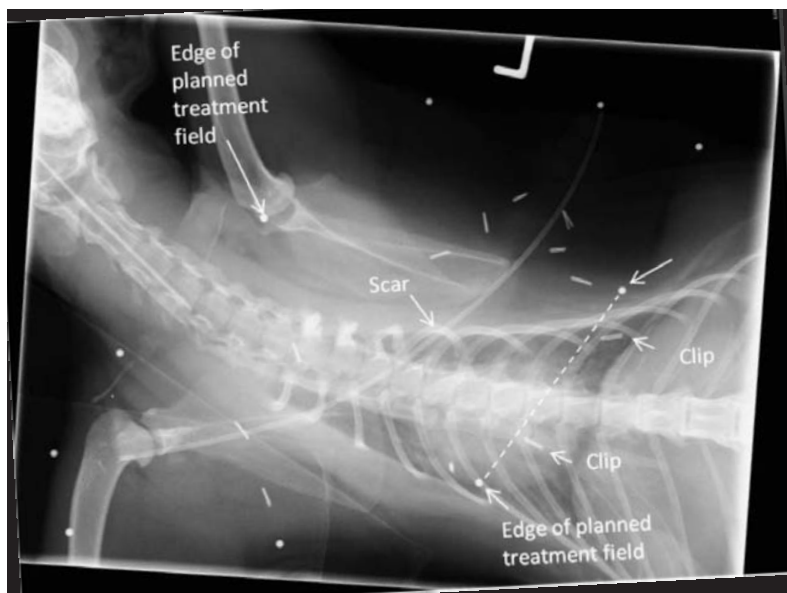
Excision of soft tissue sarcomas, which may have extensive fronds of invading tumour cells, is particularly challenging in small patients, and compartmental excision is only achievable for tumours on (distal) limbs.

#### Radiotherapy

Radiation therapy is most often used either as a postoperative adjunctive therapy, ideally in a minimal residual disease setting, or palliatively in the face of unresectable gross disease. When

radiation is used postoperatively, it is very important to ensure that the radiation therapist is aware of the original tumour site, extent and dimensions, or the planned radiation field may not include all of the affected tissue. This can result in a geographical miss, where microscopic residual disease is not included in the treated area. The risk of geographical miss increases as repeat surgeries are performed and normal anatomy becomes increasingly distorted.

The best results are likely to be achieved if radiotherapy is considered prior to surgery, and presurgical measurements and images are available (ie, photographs with measurements, drawings, radiographic or other images) to help plan the treatment. Placement of metal surgical clips at the margins of the surgical bed also helps to avoid geographical miss during radiotherapy, as there may be migration of subcutaneous tissues that may contain residual tumour (Figure 8).



**Figure 8** Dorsoventral radiograph obtained to check the radiation field in an adult MN DSH cat receiving postoperative adjunctive radiation therapy for an incompletely resected soft tissue sarcoma. The solid line is the scar, and dots represent a margin round this of 5 cm. Two of the dots along the caudal margin are joined by a dotted line to show where the caudal edge of the treatment field lies. Two clips are positioned beyond (caudal to) this margin, indicating that a larger margin must be used. This illustrates the limitations of basing radiation treatment fields on surgical scars

In the clinic, radiation therapy is used to treat feline patients in a variety of ways (see box).

- ❖ **Pituitary tumours** in acromegalic cats (Figure 6) are one of the most common indications for teletherapy.
- ❖ **Soft tissue sarcomas** (Figures 8 and 9) are also commonly treated using teletherapy, mostly following surgical resection. The majority of the published work in this area has focused on injection site-associated sarcomas. Good presurgical tumour recording is essential for these patients, and the risk of recurrence is greater if radiation is carried out after multiple surgeries.
- ❖ **Nasal and paranasal tumours** (Figure 6b,c) may be treated with radiotherapy, and this is the treatment of choice for nasal carcinomas. Its use in nasal lymphoma is controversial as these cats may relapse with lymphoma in other sites. In the author's hospital, patients with nasal lymphoma are most often treated with chemotherapy, with radiation used as a rescue therapy if there is relapse of the nasal disease. A study comparing survival in patients treated with radiotherapy alone, chemotherapy alone, or both modalities, showed no difference in outcome between groups.<sup>12</sup>
- ❖ **Abdominal cavity lymphoma** has more recently been treated with radiation therapy used in conjunction with chemotherapy or as a rescue therapy.<sup>13,14</sup>
- ❖ **Oral squamous cell carcinoma** (Figure 10) has been treated with a variety of radiation therapy protocols, but results have been fairly disappointing, with short median survival

### Radiotherapy methods used in cats


- ❖ **Systemic administration** of iodine 131 (gamma and beta emitter) is used, for example, to treat hyperthyroidism.
- ❖ **Brachytherapy** (internal radiation therapy) using a strontium 90 wand, which produces beta particles with a maximum penetration of 3–4 mm, is used to treat superficial (non-oral) squamous cell carcinoma.
- ❖ **Teletherapy** (external beam radiation) is delivered using linear accelerators producing x-rays (photons) at 4–20 MV. These high energy x-rays are deeply penetrating, and high energy beams allow a more uniform distribution of dose, particularly for deep tumours and those involving bone. Some linear accelerators also produce electrons in a range of energies, which are variably penetrating, allowing treatment of superficial lesions and avoidance of toxicity to deep structures, which is useful in small patients like cats. Radiation therapy using these sources requires multiple treatments (usually between three and 20) delivered under general anaesthesia.

**Radiation therapy is most often used as a postoperative adjunctive therapy, or palliatively in the face of unresectable gross disease.**

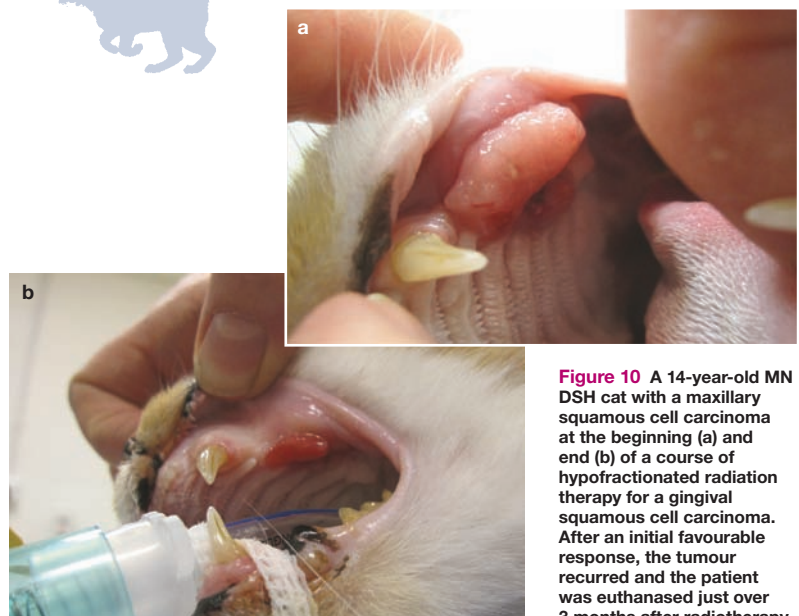


times (2 or 3 months in most studies).<sup>15–17</sup> Oncologists continue to try to find an effective protocol for this disease, with limited success, though a recent pilot study of multimodality therapy reported survival of greater than a year in 3/6 cats.<sup>18</sup>

- ❖ **Superficial cutaneous or rhinarial squamous cell carcinoma** may be treated using electrons of different energies, with their variable penetrations, though treatment with strontium is preferred as this can be delivered as a single treatment rather than multiple fractions. Photodynamic therapy (PDT) may also be appropriate for superficial lesions, but recurrence is common. Either radiotherapy or PDT may achieve long-term control after a single treatment in very superficial lesions,<sup>19</sup> but relapse is more common after PDT.<sup>20,21</sup> Topical imiquimod has also been reported to produce clinical remission. For invasive tumours, surgical excision is the treatment of choice.



**Figure 9** A 9-year-old MN Birman being prepared for postoperative adjunctive radiation therapy using electrons, for treatment of an incompletely excised, high grade injection site-associated sarcoma. The electron applicator has a cut out made to shape the field for the individual patient. The treatment field is illuminated on the patient. Unfortunately, this cat, which also received chemotherapy with epirubicin, developed widespread metastatic disease (but no local recurrence) 18 months after radiotherapy



**Figure 10** A 14-year-old MN DSH cat with a maxillary squamous cell carcinoma at the beginning (a) and end (b) of a course of hypofractionated radiation therapy for a gingival squamous cell carcinoma. After an initial favourable response, the tumour recurred and the patient was euthanased just over 3 months after radiotherapy

## Chemotherapy

Chemotherapy is used where systemic delivery of treatment is required to treat widely disseminated but chemoresponsive disease (eg, lymphoma) or where there is a high risk of development of metastatic disease and micrometastases are likely to be present (eg, some high grade sarcomas). It is generally not a suitable option as the primary treatment for a large solid non-lymphoid tumour, which is likely to be poorly chemosensitive.

✦ **Lymphoma** The optimum protocol for feline lymphoma remains to be determined.<sup>22–24</sup> This, at least in part, reflects the larger variation in clinical forms of lymphoma seen in cats compared with dogs. The role of doxorubicin/epirubicin remains controversial.<sup>22,24,25</sup> Lymphoma is reviewed elsewhere<sup>26–30</sup> and extranodal disease within the current special issue. Some cats with lymphoma will respond very well to chemotherapy, and the best prognostic indicator is achieving complete remission. Individual cats may need more adjustment of their protocol than dogs, but this is not insurmountable. The major challenge in treating feline lymphoma remains the poor response of cats to rescue therapy compared with dogs, though some cats will do well with lomustine as a rescue agent.<sup>31</sup>

✦ **Soft tissue sarcoma** The impact of chemotherapy on survival of cats with high grade (grade 3) soft tissue sarcomas is unproven, with most work concentrating on injection site/vaccine-associated sarcomas.<sup>32,33</sup> However, there may be a positive impact on disease-free interval and possibly local tumour control in patients receiving radiotherapy and chemotherapy with doxorubicin,<sup>33,34</sup> and multimodality treatment is recommended.<sup>35</sup>

✦ **Mast cell tumour** Chemotherapy is less commonly used for the other tumours that



**Chemotherapy is used to treat widely disseminated but chemoresponsive disease (eg, lymphoma) or where there is a high risk of development of metastatic disease.**

readers may be familiar with in dogs (eg, metastatic mast cell tumours, osteosarcoma), because of differing biological behaviour of the tumours, and differing responses and drug toxicities across species. The role of chemotherapy for palliative or adjuvant treatment of feline mast cell tumours has not been clearly established,<sup>36</sup> and chemotherapy is generally reserved for cats with histologically poorly differentiated, locally invasive and/or metastatic tumours. Vinblastine, chlorambucil and lomustine have been used. One study reports an overall response rate of 50% in cats with measurable disease treated with lomustine, and a median duration of response of 168 days.<sup>37</sup> There is no proven role for corticosteroids in the treatment of feline mast cell tumours.

Further discussion on the use of chemotherapy and targeted therapies in cats, with a particular focus on the idiosyncracies of feline patients, is provided in an accompanying article in this special issue.

## Funding

The author received no specific grant from any funding agency in the public, commercial or not-for-profit sectors for the preparation of this article.

## Conflict of interest

The author does not have any potential conflicts of interest to declare.

### Targeted therapies

Tyrosine kinase inhibitors (TKIs) have been used to treat cats with cancer, though neither masitinib nor toceranib is licensed in this species. There is limited data on toxicity and efficacy. The main target tumours are mast cell tumours, injection site/vaccine-associated sarcomas and possibly squamous cell carcinoma. Combination TKI and radiation therapy is being investigated in the treatment of sarcomas and oral squamous cell carcinomas. The main potential toxicities of the TKIs are gastrointestinal toxicity and myelosuppression, and nephrotoxicity should also be monitored for.

## KEY POINTS

- ✦ Cancer is a differential for cats with mass lesions and many non-specific clinical signs.
- ✦ For many cancers in cats, early treatment holds the only chance of cure: raising awareness is important, particularly for squamous cell carcinomas and soft tissue sarcomas.
- ✦ Diagnosis and staging inform clinical decision making; tests should be chosen sensibly (and cost effectively when funds are limited), based on the information required.
- ✦ Inappropriate excisional biopsy can jeopardise future treatment, particularly for soft tissue sarcomas.
- ✦ Radiotherapy and chemotherapy are evolving fields in feline medicine and there is still much to learn.

## References

- 1 Goldfinch N and Argyle DJ. **Feline lung–digit syndrome: unusual metastatic patterns of primary lung tumours in cats.** *J Feline Med Surg* 2012; 14: 202–208.
- 2 Corr SA and Blackwood L. **What is your diagnosis? Primary pulmonary tumour (carcinoma) with digital metastases.** *J Small Anim Pract* 2003; 44: 201, 240–xiii.
- 3 Kasabalis D, Mylonakis ME, Patsikas MN, Petanides T and Koutinas AF. **Paraneoplastic exfoliative erythroderma in a cat with thymoma.** *J Hellenic Vet Med Soc* 2011; 62: 229–234.
- 4 Smits B and Reid MM. **Feline paraneoplastic syndrome associated with thymoma.** *N Z Vet J* 2003; 51: 244–247.
- 5 Tasker S, Griffon DJ, Nuttall TJ and Hill PB. **Resolution of paraneoplastic alopecia following surgical removal of a pancreatic carcinoma in a cat.** *J Small Anim Pract* 1999; 40: 16–19.
- 6 Marconato L, Albanese F, Viacava P, Marchetti V and Abramo F. **Paraneoplastic alopecia associated with hepatocellular carcinoma in a cat.** *Vet Dermatol* 2007; 18: 267–271.
- 7 Scott KD, Zoran DL, Mansell J, Norby B and Willard MD. **Utility of endoscopic biopsies of the duodenum and ileum for diagnosis of inflammatory bowel disease and small cell lymphoma in cats.** *J Vet Intern Med* 2011; 25: 1253–1257.
- 8 Murphy S. **Skin neoplasia in small animals 3. Common canine tumours.** *In Pract* 2006; 28: 398–402.
- 9 Forrest LJ and Graybush CA. **Radiographic patterns of pulmonary metastasis in 25 cats.** *Vet Radiol Ultrasound* 1998; 39: 4–8.
- 10 Ballegeer EA, Forrest LJ and Stepien RL. **Radiographic appearance of bronchoalveolar carcinoma in nine cats.** *Vet Radiol Ultrasound* 2002; 43: 267–271.
- 11 Gabor LJ, Canfield PJ and Malik R. **Haematological and biochemical findings in cats in Australia with lymphosarcoma.** *Aust Vet J* 2000; 78: 456–461.
- 12 Haney SM, Beaver L, Turrel J, Clifford CA, Klein MK, Crawford S, et al. **Survival analysis of 97 cats with nasal lymphoma: a multi-institutional retrospective study (1986–2006).** *J Vet Intern Med* 2009; 23: 287–294.
- 13 Parshley DL, LaRue SM, Kitchell B, Heller D and Dhaliwal RS. **Abdominal irradiation as a rescue therapy for feline gastrointestinal lymphoma: a retrospective study of 11 cats (2001–2008).** *J Feline Med Surg* 2011; 13: 63–68.
- 14 Williams LE, Pruitt AF and Thrall DE. **Chemotherapy followed by abdominal cavity irradiation for feline lymphoblastic lymphoma.** *Vet Radiol Ultrasound* 2010; 51: 681–687.
- 15 Fidel JL, Sellon RK, Houston RK and Wheeler BA. **A nine-day accelerated radiation protocol for feline squamous cell carcinoma.** *Vet Radiol Ultrasound* 2007; 48: 482–485.
- 16 Bregazzi VS, LaRue SM, Powers BE, Fettman MJ, Ogilvie GK and Withrow SJ. **Response of feline oral squamous cell carcinoma to palliative radiation therapy.** *Vet Radiol Ultrasound* 2001; 42: 77–79.
- 17 McDonald C, Looper J and Greene S. **Response rate and duration associated with a 4gy 5 fraction palliative radiation protocol.** *Vet Radiol Ultrasound* 2012; 53: 358–364.
- 18 Marconato L, Buchholz J, Keller M, Bettini G, Valenti P and Kaser-Hotz B. **Multimodal therapeutic approach and interdisciplinary challenge for the treatment of unresectable head and neck squamous cell carcinoma in six cats: a pilot study.** *Vet Comp Oncol*. Epub ahead of print 23 March 2012. DOI: 10.1111/j.1476-5829.2011.00304.x.
- 19 Hammond GM, Gordon IK, Theon AP and Kent MS. **Evaluation of strontium Sr 90 for the treatment of superficial squamous cell carcinoma of the nasal planum in cats: 49 cases (1990–2006).** *J Am Vet Med Assoc* 2007; 231: 736–741.
- 20 Buchholz J, Wergin M, Walt H, Gräfe S, Bley CR and Kaser-Hotz B. **Photodynamic therapy of feline cutaneous squamous cell carcinoma using a newly developed liposomal photosensitizer: preliminary results concerning drug safety and efficacy.** *J Vet Intern Med* 2007; 21: 770–775.
- 21 Bexfield NH, Stell AJ, Gear RN and Dobson JM. **Photodynamic therapy of superficial nasal planum squamous cell carcinomas in cats: 55 cases.** *J Vet Intern Med* 2008; 22: 1385–1389.
- 22 Milner RJ, Peyton J, Cooke K, Fox LE, Gallagher A, Gordon P, et al. **Response rates and survival times for cats with lymphoma treated with the University of Wisconsin–Madison chemotherapy protocol: 38 cases (1996–2003).** *J Am Vet Med Assoc* 2005; 227: 1118–1122.
- 23 Teske E, Van Straten G, Van Noort R and Rutteman GR. **Chemotherapy with cyclophosphamide, vincristine, and prednisolone (COP) in cats with malignant lymphoma: new results with an old protocol.** *J Vet Intern Med* 2002; 16: 179–186.
- 24 Simon D, Eberle N, Laacke-Singer L and Nolte I. **Combination chemotherapy in feline lymphoma: treatment outcome, tolerability, and duration in 23 cats.** *J Vet Intern Med* 2008; 22: 394–400.
- 25 Oberthaler KT, Mauldin E, McManus PM, Shofer FS and Sorenmo KU. **Rescue therapy with doxorubicin-based chemotherapy for relapsing or refractory feline lymphoma: a retrospective study of 23 cases.** *J Feline Med Surg* 2009; 11: 259–265.
- 26 Hayes A. **Feline lymphoma 1. Principles of diagnosis and management.** *In Pract* 2006; 28: 516–524.
- 27 Hayes A. **Feline lymphoma 2. Specific disease presentations.** *In Pract* 2006; 28: 578–585.
- 28 Lingard AE, Briscoe K, Beatty JA, Moore AS, Crowley AM, Krockenberger M, et al. **Low-grade alimentary lymphoma: clinicopathological findings and response to treatment in 17 cases.** *J Feline Med Surg* 2009; 11: 692–700.
- 29 Barrs VR and Beatty JA. **Feline alimentary lymphoma: 1. Classification, risk factors, clinical signs and non-invasive diagnostics.** *J Feline Med Surg* 2012; 14: 182–190.
- 30 Barrs VR and Beatty JA. **Feline alimentary lymphoma: 2. Further diagnostics, therapy and prognosis.** *J Feline Med Surg* 2012; 14: 191–201.
- 31 Dutelle AL, Bulman-Fleming JC, Lewis CA and Rosenberg MP. **Evaluation of lomustine as a rescue agent for cats with resistant lymphoma.** *J Feline Med Surg* 2012; 14: 694–700.
- 32 Eckstein C, Guscetti F, Roos M, Martín de Las Mulas J, Kaser-Hotz B and Rohrer Bley C. **A retrospective analysis of radiation therapy for the treatment of feline vaccine-associated sarcoma.** *Vet Comp Oncol* 2009; 7: 54–68.
- 33 Hahn KA, Endicott MM, King GK and Harris-King FD. **Evaluation of radiotherapy alone or in combination with doxorubicin chemotherapy for the treatment of cats with incompletely excised soft tissue sarcomas: 71 cases (1989–1999).** *J Am Vet Med Assoc* 2007; 231: 742–745.
- 34 Poirier VJ, Thamm DH, Kurzman ID, Jeglum KA, Chun R, Obradovich JE, et al. **Liposome-encapsulated doxorubicin (Doxil) and doxorubicin in the treatment of vaccine-associated sarcoma in cats.** *J Vet Intern Med* 2002; 16: 726–731.
- 35 Martano M, Morello E and Buracco P. **Feline injection-site sarcoma: past, present and future perspectives.** *Vet J* 2011; 188: 136–141.
- 36 Henry CJ and Herrera CL. **Mast cell tumors in cats: clinical update and possible new treatment avenues.** *J Feline Med Surg* 2013; 15: 41–47.
- 37 Rassnick KM, Williams LE, Kristal O, Al-Sarraf R, Baez JL, Zwahlen CH, et al. **Lomustine for treatment of mast cell tumors in cats: 38 cases (1999–2005).** *J Am Vet Med Assoc* 2008; 232: 1200–1205.